

Urethral diverticulum: An unknown pathology

Hamedoun Larbi^{1*}; Hassan Iliass¹; Cherraqi Amine²; Akim Kogui N'Douro¹; Mrabti Mohamed¹; Alami mohamed¹; Ameer Ahmed¹

¹Urology Department, Military Hospital of Instruction Mohamed V, Hay Ryad - 10100 RABAT, Morocco.

²Radiology Department, Military Hospital of Instruction Mohamed V, Hay Ryad - 10100 RABAT, Morocco.

***Corresponding Author: Hamedoun Larbi**

Urology Department, Military Hospital of Instruction Mohamed V, Hay Ryad - 10100 RABAT, Morocco.

Email: larbi771@gmail.com

Description

The A 25 year old female patient, pregnant at 30 weeks' gestation, with no particular medical history, presented to the clinic with urethral pain.

The interrogation reveals a dysuria evolving for more than 7 months, with a urethral pain progressively increasing in intensity and a dyspareunia preventing any sexual act for the couple.

The clinical examination in gynecological position found a rounded swelling developed in the anterior wall of the vagina.

The vaginal touch: allowed the appreciation of the volume, of the consistency. Also, a small pressure on the mass caused cloudy urine to come out, confirming the communication between the pouch and the urethra.

The MRI objectified a urethral diverticulum of the left posterolateral wall measuring 22 X 15 mm.

The therapeutic attitude is abstinence until delivery then the patient will be proposed to a surgical cure.

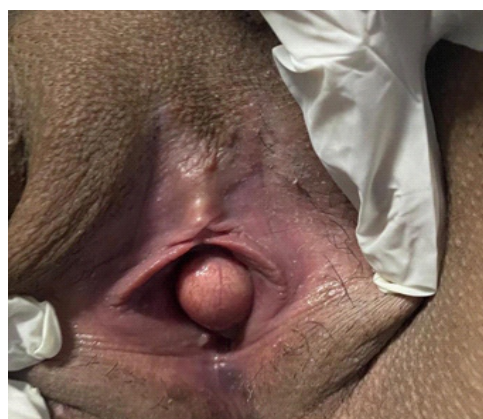


Figure 1: Clinical appearance of the urethral diverticulum.

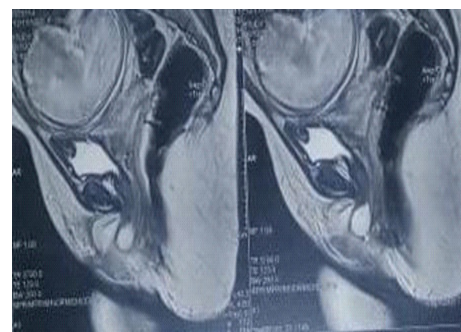


Figure 2: Sagittal section of MRI in T2 sequence showing the precise location of the urethral diverticulum.

Received: Feb 10, 2022

Accepted: Mar 25, 2022

Published: Mar 31, 2022

Archived: www.bioaccent.org

Copyright: © Larbi H (2022).