

Image Article

## A Rare Case of Renocolic Fistula

Jabri Youssef<sup>1</sup>, Slaoui Amine<sup>1\*</sup> Regragui Souhail<sup>1</sup>, Lamchahab Hamza<sup>1</sup>

Karmouni Tariq<sup>1</sup>, Elkhader Khalid<sup>1</sup>, Koutani Abdellatif<sup>1</sup> and Ibnattya Ahmed<sup>1</sup>

<sup>1</sup>Urology Department, Ibn Sina Hospital, Mohamed V University, Rabat, Morocco

Uro-digestive fistulas represent abnormal communication between the urinary tract and the digestive tract. They can be high intraperitoneally mainly enterovetic or low subperitoneal urethro-prostato-rectal. We report the case of a patient presenting pneumaturia, occurring at the end of urination, with foamy urines. The scanner shows a renocolic fistula. It benefited at first by an ileos to my with drainage of the pyonephrosis. Then in a second temos of a nephrectomy and a restoration of digestive continuity.

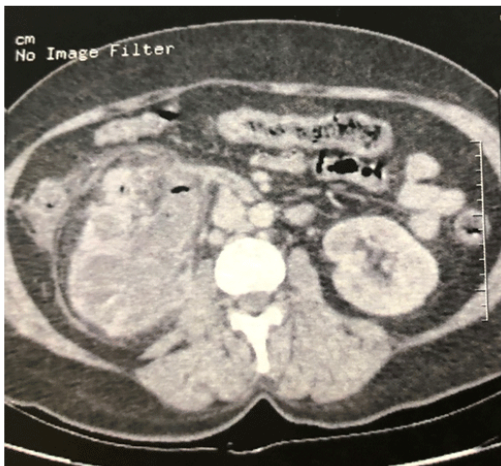

Figure 1. Transverse CT scan section showing renocolic fistula

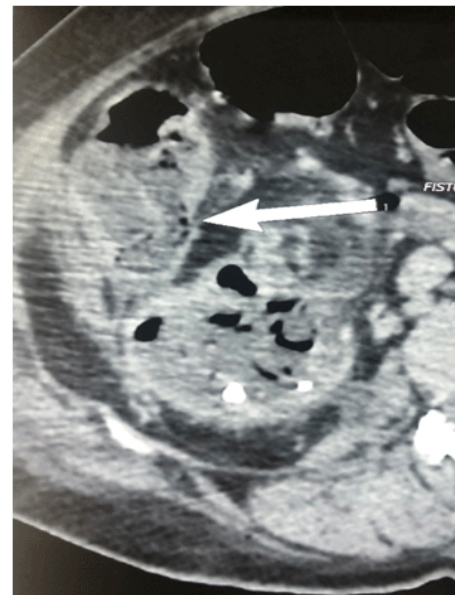


Figure 2. Sagittal CT scan section showing renocolic fistula

**\*Corresponding Author:** Slaoui Amine, urology B Department, Ibn Sina hospital, Mohammed V University, Rabat, Morocco, E-mail: amineslaoui05@gmail.com

**Sub Date:** August 20<sup>th</sup> 2019, **Acc Date:** August 22<sup>nd</sup> 2019, **Pub Date:** August 22<sup>nd</sup> 2019

**Citation:** Slaoui A, Jabri Y, Regragui s, et al. (2019) A Rare Case of Renocolic Fistula. BAOJ Urol Nephrol 4: 037

**Copyright:** © 2019 Slaoui Amine, et al. This is an open access article distributed under the terms of the Creative Commons Attribution License, which permits unrestricted use, distribution, and reproduction in any medium, provided the original author and source are credited.