

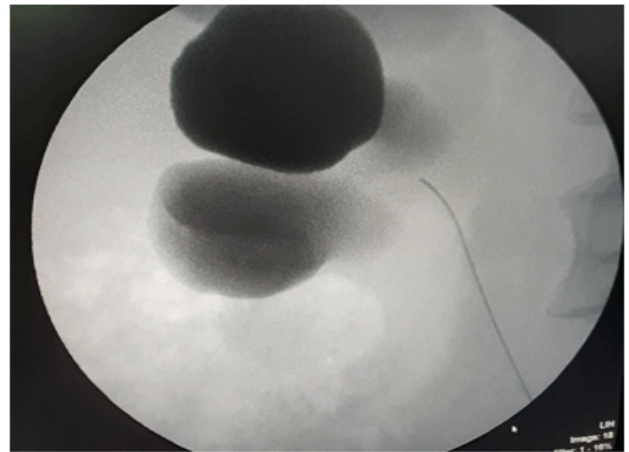
Image Article

## Caliceal Diverticula Revealed by Iterativeurinary Infections

Jabri Y<sup>1</sup>, Slaoui A<sup>1\*</sup>, Regragui Souhail<sup>1</sup>, Karmouni T<sup>1</sup>, Elkhader K<sup>1</sup>, Koutani A<sup>1</sup> and Ibnattya A<sup>1</sup>

<sup>1</sup>Urology B Department Chu Ibn Sina, Mohammed V University, Rabat, Morocco

A 69 years old woman who consulted with right lumbar pain and urinary infections. Retrograde pyelography revealed a Caliceal diverticula in the right kidney. Caliceal diverticula are “eventrations of the upper collecting system, lying within the renal parenchyma and communicating with the main collecting system via a narrow channel.” They are lined by transitional cell epithelium but do not directly receive drainage from a renal papilla. Noted in 0.5% of the population.



**Figure.** Retrograde pyelography revealed a Caliceal diverticula in the right kidney.

**\*Corresponding Author:** Slaoui Amine, urology B Department, Ibn Sina hospital, Mohammed V University, Rabat, Morocco, E-mail: amineslaoui05@gmail.com

**Sub Date:** May 29<sup>th</sup> 2019, **Acc Date:** June 4<sup>th</sup> 2019, **Pub Date:** June 5<sup>th</sup> 2019

**Citation:** Jabri Y, slaoui A, Souhail R, Karmouni T, et al. (2019) Caliceal Diverticula Revealed by Iterativeurinary Infections. BAOJ Urol Nephrol 4: 029

**Copyright:** © 2019 Slaoui A. This is an open access article distributed under the terms of the Creative Commons Attribution License, which permits unrestricted use, distribution, and reproduction in any medium, provided the original author and source are credited.