

Image article

Junctional Syndrome on Pelvic Kidney Mimicking a Giant Ovarian Cyst

Slaoui A^{1*}, Regragui S¹, Himmi Y¹, Lamzef Y¹, BilgoAbdulaziz¹, Karmouni T¹, Elkhader K¹,
 Koutani A¹ and Ibnattya A¹

¹Urology B Department Chu Ibn Sina, Mohammed V University, Rabat, Morocco

This is a young woman of 25 years without significant pathological ATCD. She presented for diffuse pelvic pain in a febrile context and deterioration of the general condition. The clinical examination finds a hypogastric mass sensitive to palpation. On the other hand, the biological assessment does not find any particular anomalies, the renal function is preserved. The Computerized tomographyurography shows a pelvic left kidney with a large pyelocalic dilatation. The kidney secretes normally but excretes with a slight delay. Finally the ureter was not visualized. This disparity in size is pathognomonic of pyelo-ureteral junction syndrome.

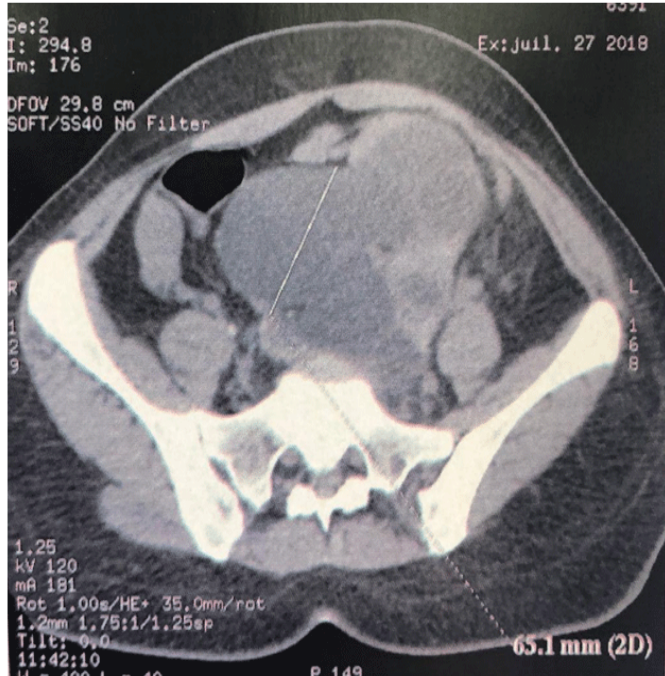


Figure 1. Transverse section of the uro-CT showing dilated renal pelvis more than 6 cm.

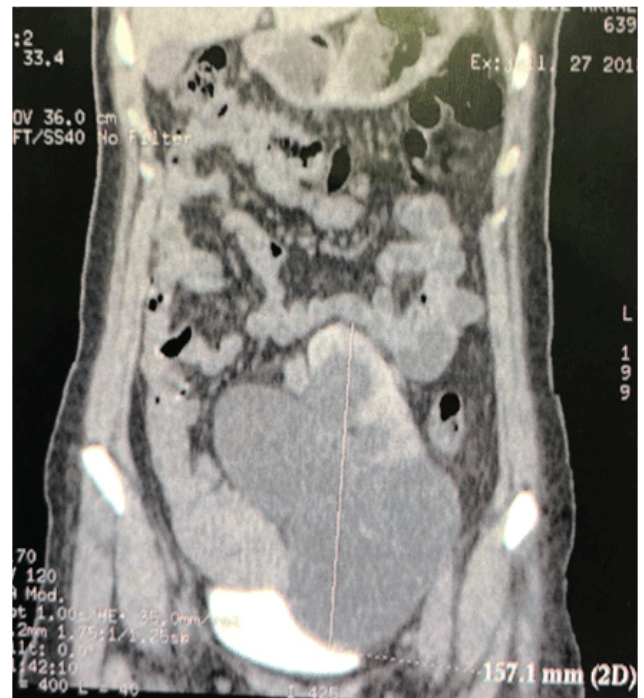


Figure 2. Coronal uro-CT showing dilated renal pelvis more than 15 cm

***Corresponding Author:** Amine Slaoui, Urology B Department, IbnSinaHospital, Mohammed V University, Rabat Morocco, E-mail: Amineslaoui05@gmail.com

Sub Date: March 4th 2019, **Acc Date:** March 6th 2019, **Pub Date:** March 7th 2019

Citation: Slaoui A, Regragui S, Himmi Y, Lamzef Y, et al. (2019) Junctional Syndrome on Pelvic Kidney Mimicking a Giant Ovarian Cyst. BAOJ Urol Nephrol 4: 019

Copyright: © 2019 Slaoui A. This is an open access article distributed under the terms of the Creative Commons Attribution License, which permits unrestricted use, distribution, and reproduction in any medium, provided the original author and source are credited.