

Image article

Crying to Relieve Pain: Interstitial Cystitis

Slaoui A^{1,2*}, Moussa I², Bakar A², Limani K², Peltier A², Karmouni T¹, Elkhader K¹, Koutani A¹, Ibnattya A¹

¹Urology B Department CHU IBN SINA, Mohammed V University, Rabat MOROCCO

²Urology Department Jules Bordet Institut, ULB Brussels BELGIUM

Cystoscopy with hydro distention are an integral part of the diagnostic assessment of bladder pain syndrome/interstitial cystitis (BPS/IC) but also have a therapeutic effect.

We report the case of a patient with cystalgia who is accompanied by a rebellious pollakiuria. Under general anesthesia we performed a cystoscopy and then a hydro distention. The serum bag is placed 1m

above the plane of the bladder (77mmHg) and we filled the bladder with 1 L of saline kept for 10 minutes in the bladder.

We noted then that during the filling this fragile mucosa “cries of blood” (Figure 1,2). A therapeutic effect allowed the patient to be relieved. An improvement in symptomatology was observed in this case for six months. A biopsy performed during cystoscopy made the diagnosis.

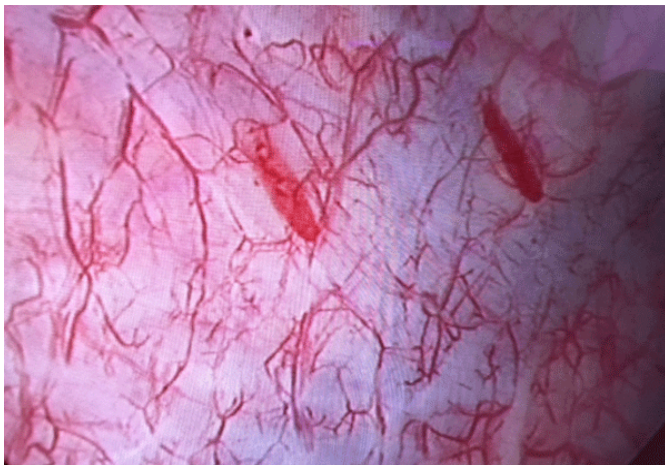

Figure 1. Aspect of the mucosa at the beginning of the hydrodistension

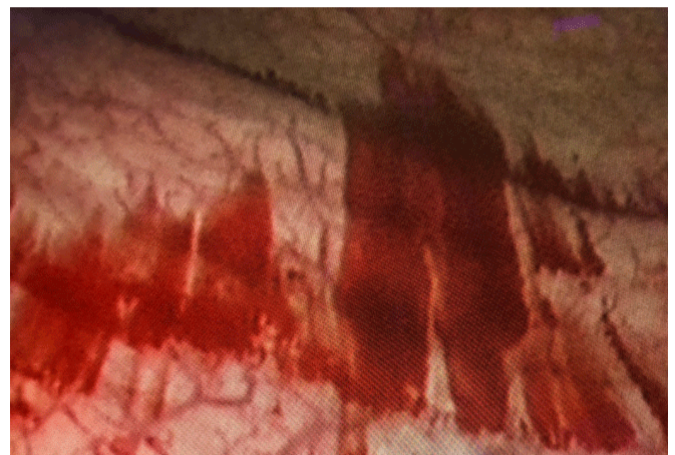


Figure 2. Aspect of the mucosa at the end of the hydrodistension

***Corresponding Author:** Amine Slaoui, Urology B Department, IbnSina Hospital, Mohammed V University, Rabat Morocco, E-mail: AmineSlaoui05@gmail.com

Sub Date: December 22nd 2018 , **Acc Date:** December 28th 2018, **Pub Date:** December 31st 2018

Citation: Slaoui A, Moussa I, Karmouni T, Elkhader K, et al. (2018) Crying to Relieve Pain: Interstitial Cystitis. BAOJ Urol Nephrol 3: 015

Copyright: © 2018 Slaoui A. This is an open access article distributed under the terms of the Creative Commons Attribution License, which permits unrestricted use, distribution, and reproduction in any medium, provided the original author and source are credited.