

Research Article

## **Fecal Incontinence (FI) in Women and its Reconstructive Surgery; The Role of Childbirth Trauma (CBT) and Perineal Lacerations in its Pathogenesis**

**Abdel Karim M El Hemaly<sup>1\*</sup>, Laila AES. Mousa<sup>2</sup>, Ibrahim M Kandil<sup>1</sup>, Muhammad R Morad<sup>1</sup>, Mervat M Ibrhaim<sup>1</sup>,  
Fatma S Al Sokkary<sup>1</sup> and Muhammad MmTahseen<sup>3</sup>**

<sup>1</sup>Professor Ob/Gyn. Faculty of medicine, Al Azhar University, Cairo, Egypt

<sup>2</sup>Professor pathology, Faculty of medicine, Al Azhar University, Cairo, Egypt

<sup>3</sup>Gynecologist at El Monira Hospital, Egypt

### **Abstract**

#### **Introduction**

Voluntary control of the passage of feces and/or flatus is gained after toilet training in early childhood. Normally the anal canal is kept empty and closed all the time, full rectum induces sensations of desire to evacuate. According to social circumstances available the person can evacuate or postpone, waiting for favorable social circumstances, by increasing the sympathetic tone at the internal anal sphincter (IAS). After toilet training control of defecation changes from the pelvic parasympathetic system control to the sympathetic nervous system control under supervision of alert healthy CNS Usual repair is in layers focusing on mending the torn edges of the EAS with either end-to-end or overlapping technique.

#### **Aim of the Study**

We introduced a new surgery stressing on the importance of the repair of the IAS in complete restoration of fecal continence.

#### **Patients and Methods**

Women with different degrees of perineal lacerations and posterior vaginal wall prolapse were assessed clinically, investigated and imaged with 3DUS and MRI. We correct FI in women with various degrees of perineal lacerations, introducing a new operation for complete perineal tear, expose the IAS (by dissecting the torn IAS clear from the posterior vaginal wall), mend the torn anal canal wall, and mend the torn IAS. Approximate the two-levator ani muscles. Strengthen

the posterior vaginal wall by overlapping the two vaginal flaps; also we add extra support to the mended IAS. Repair the perineum.

#### **Results**

Continence is gained immediately and on long term.

#### **Discussion**

Classically, to treat complete perineal tear is mainly to repair the EAS either end-to-end by overlapping the two ends of the EAS which often results in failure to gain fecal continence. Fecal continence depends on healthy CNS, thoraco-lumbar sympathetic nerves and an intact healthy IAS. Repair of torn IAS is the corner-stone of restoring FI.

**\*Corresponding Author:** Abdel Karim M El Hemaly, Faculty of medicine, Al Azhar University, Cairo, Egypt, Tel: +2 01001577969; E-mail: profakhemaly@hotmail.com

**Sub Date:** November 30<sup>th</sup> 2018 **Acc Date:** : December 10<sup>th</sup> 2018, **Pub Date:** December 11<sup>th</sup> 2018

**Citation:** Abdel Karim MEH, Mousa LA, Kandil IM. et al. (2018) Fecal Incontinence (FI) in Women and its Reconstructive Surgery;The Role of Childbirth Trauma (CBT) and Perineal Lacerations in its Pathogenesis. BAOJ Cancer Res Ther 4: 058.

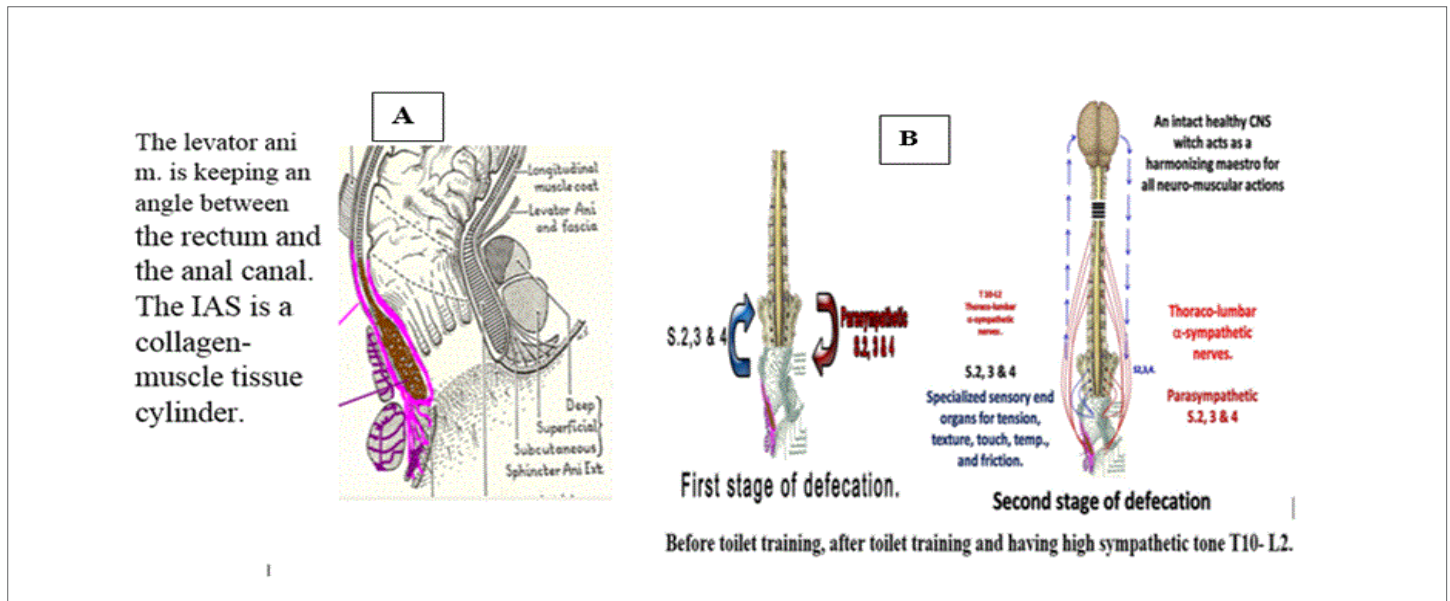
**Copyright:** © 2018 Abdel Karim MEH. This is an open access article distributed under the terms of the Creative Commons Attribution License, which permits unrestricted use, distribution, and reproduction in any medium, provided the original author and source are credited.

**Keywords:** Fecal Incontinence (FI); Internal Anal Sphincter (IAS); External Anal Sphincter (EAS); Central Nervous System (CNS); Sympathetic Nerves; Parasympathetic Nerves

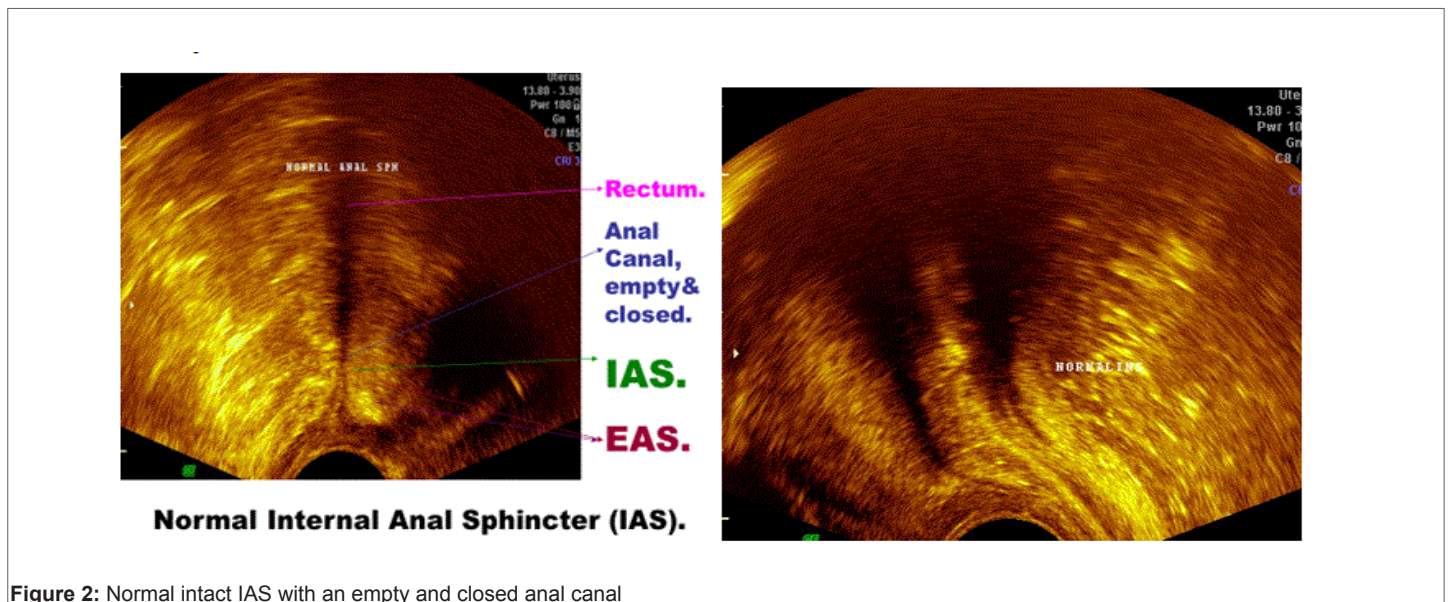
## Introduction

Fecal continence depends mainly on two main factors, the first is an inherent factor and the other is an acquired factor. The inherent factor is the presence of an intact strong internal anal sphincter (IAS). The IAS is a collagen-muscle tissue cylinder that surrounds the anal canal and is surrounded in its lower part with the external anal sphincter (EAS). The EAS is a striated voluntary muscle, divided into three parts,

subcutaneous, superficial and deep parts. It is innervated through the systemic voluntary nervous system via the pudendal nerves. The IAS is composed mainly of collagen tissue cylinder with plain smooth muscle fibers lying on and intermingles with the strong collagen sheet in its mid thickness. Its nerve supply is from the thoraco-lumbar sympathetic nerves (T10-L2) through the superior and inferior hypogastric nerves [1, 2, 3, 4, 5, 6]. Toilet training turns fecal expulsion from involuntary parasympathetic sacral reflex to voluntary complex neuro-muscular actions harmonized by healthy alert central nervous system (CNS) and the thoraco-lumbar sympathetic control [6, 7, 8, 9, 10 & 11]. The IAS is intimately related to the posterior vaginal wall, Figures 1, 2, 3, 4, and 5. 6 & 7.



**Figure 1:** Diagrammatic representation of the IAS and the EAS in image A. Image B explains defecation before toilet training is pelvic parasympathetic. Toilet training switches it to thoraco-lumbar sympathetic controlled by intact healthy CNS



**Figure 2:** Normal intact IAS with an empty and closed anal canal

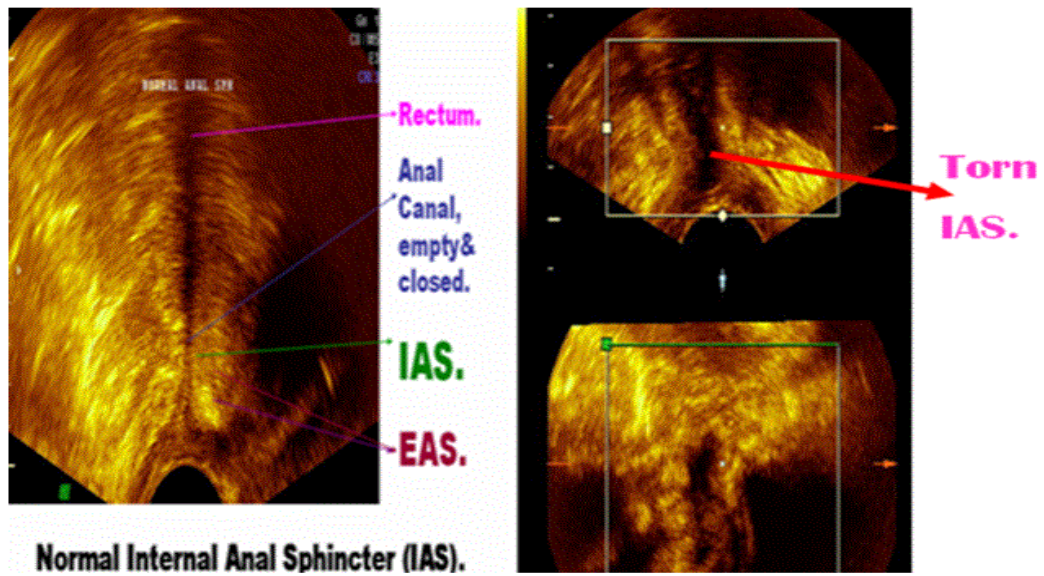


Figure 3: Images with 3DUS of the IAS, the anal canal and the rectum. On the right the IAS is torn leading to an open anal canal with FI.

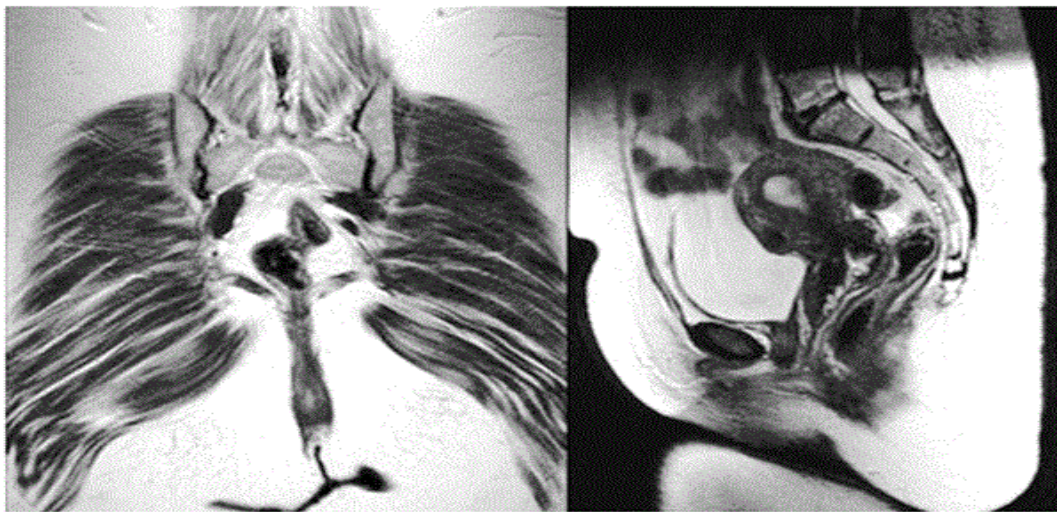
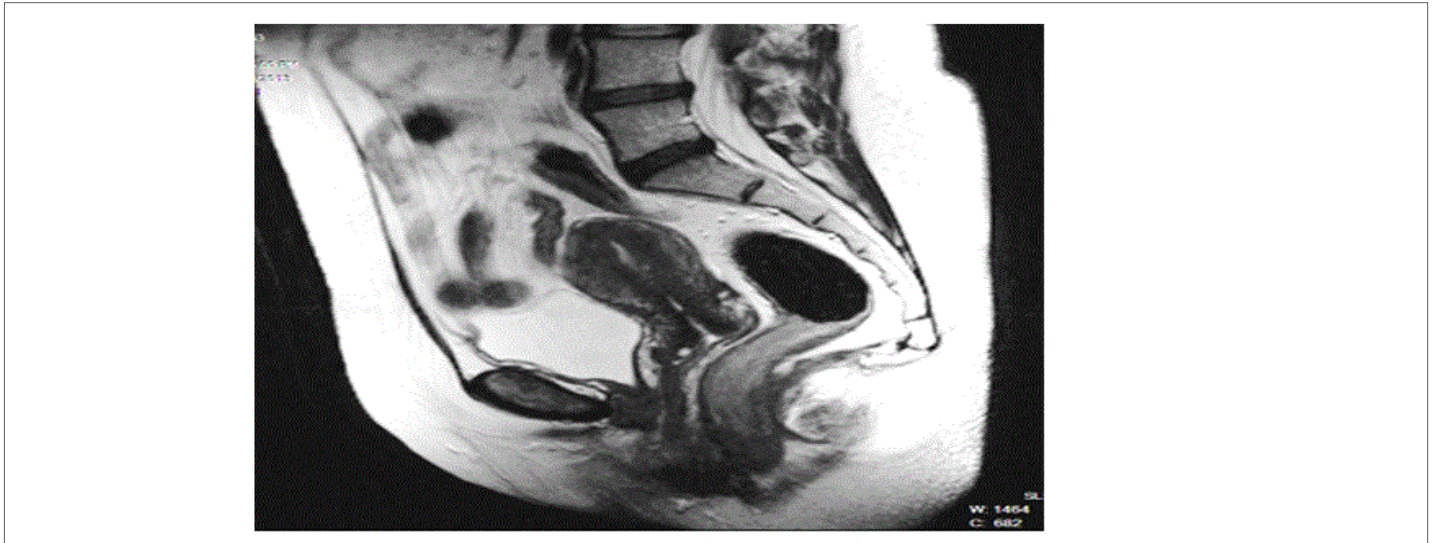
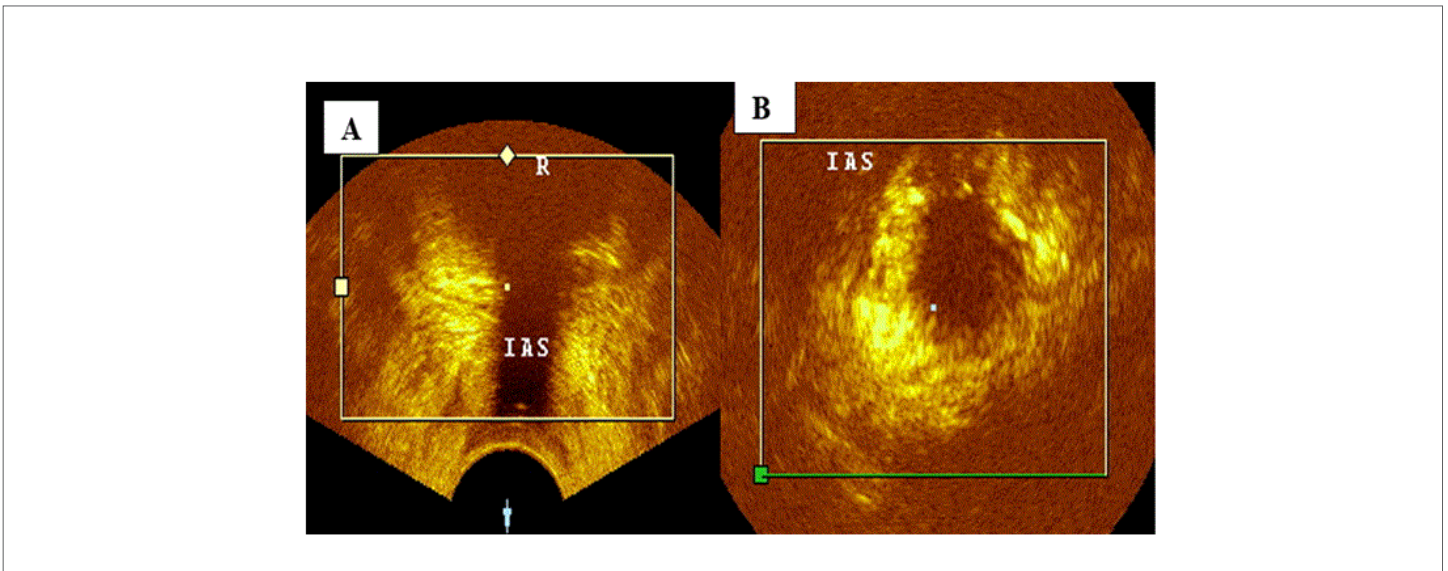


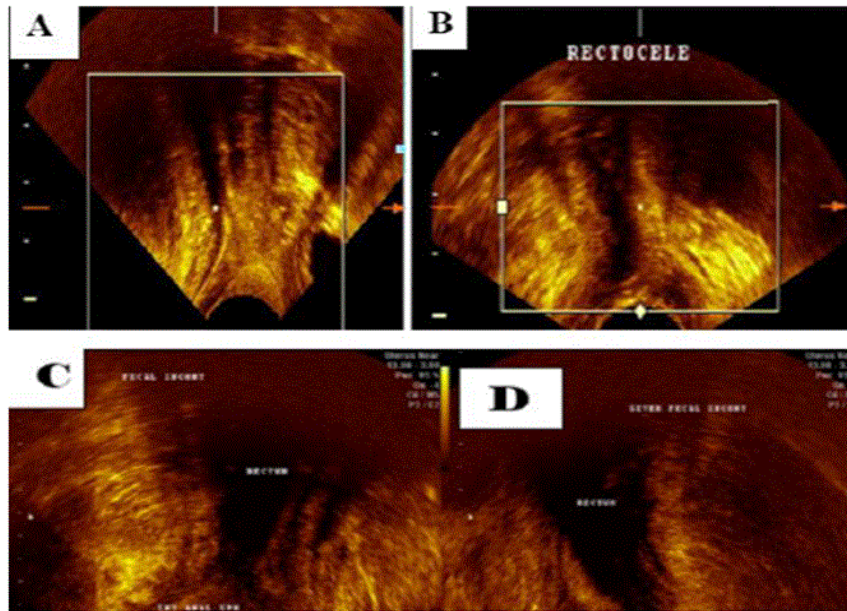
Figure 4: MRI images show torn IAS with passage of rectal contents



**Figure 5:** An Image with Mri In A Patient With Vaginal Walls Prolapse And Also Complains Of Sui And Fi. The Image Shows Torn Ius And Torn Isa With Passage Of Flatus.



**Figure 6:** Two images with 3DUS of a patient with FI. Image A is a coronal section shows torn IAS with an open anal canal. Image B is a cross section at the cursor point shows a horse-shoe appearance of torn IAS.

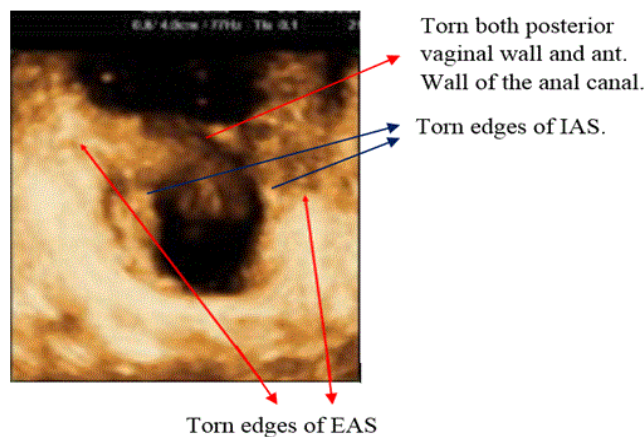


**Figure 7:** Four images with 3DUS of the anal canal and rectum, image (A) and (B) are lateral views, image (A) shows normal rectum and normal internal anal sphincter (IAS) with closed and empty anal canal. Image (B) shows an open anal canal with torn IAS. Images (C&D) are coronal sections show the anal canal is open with torn IAS in patients with FI.

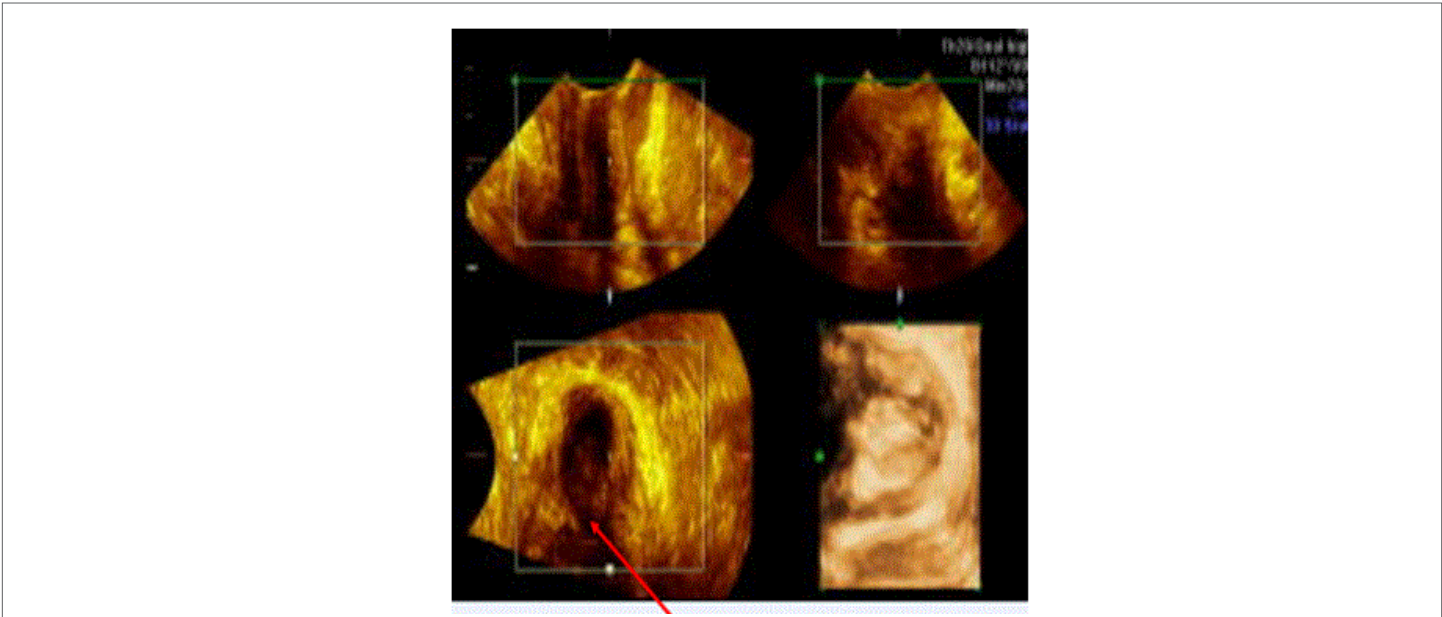
Childbirth trauma (CBT) causes invisible lacerations in the collagen chassis of the posterior vaginal wall leading to posterior vaginal wall prolapse; and it may cause different degrees of perineal lacerations. It also leads to laceration of the IAS with subsequent FI. Any correction which does not include correction of the torn IAS does not cure FI.

### Patients and Methods

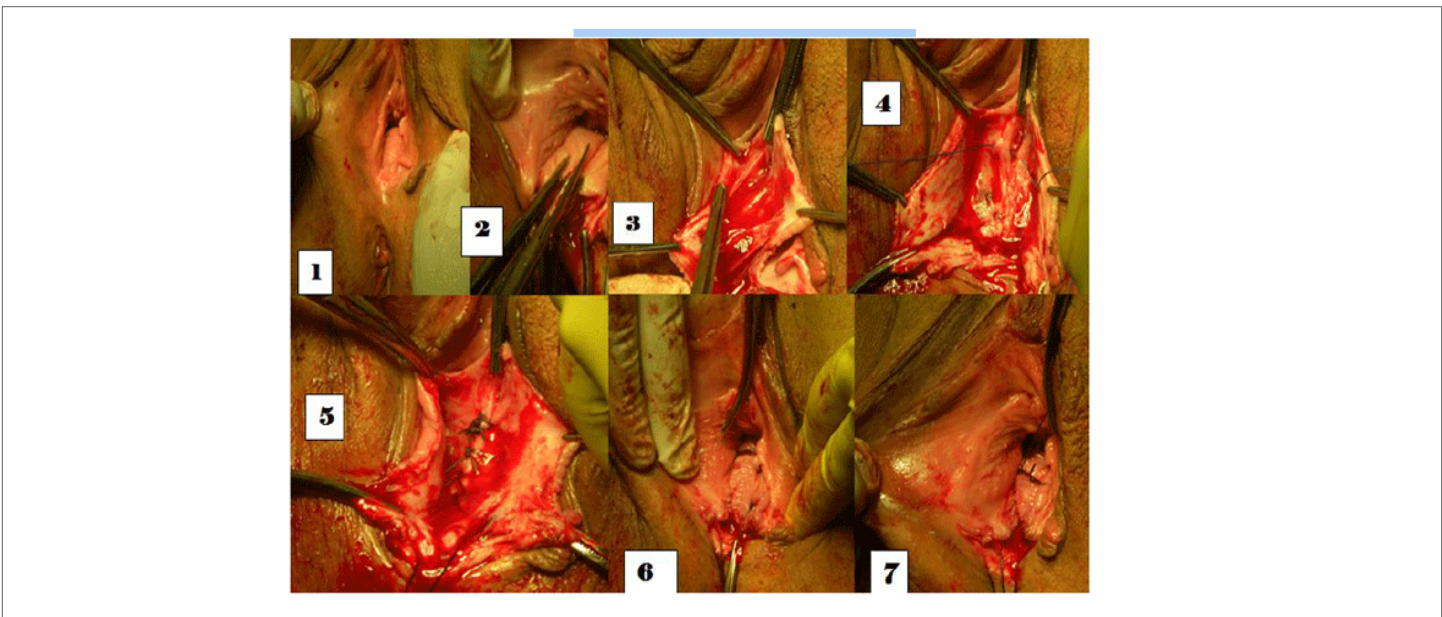
Patients complaining of FI were chosen for the study. They were parous patients who had vaginal delivery/deliveries. Concomitant anterior vaginal wall prolapse and urinary incontinence are usually present. Two hundred and fifty patients with FI were chosen for the study. All patients had posterior vaginal wall prolapse, twelve of them had third degree perineal lacerations, and six had fourth degree perineal lacerations Figures 8, 9, 11 & 12.



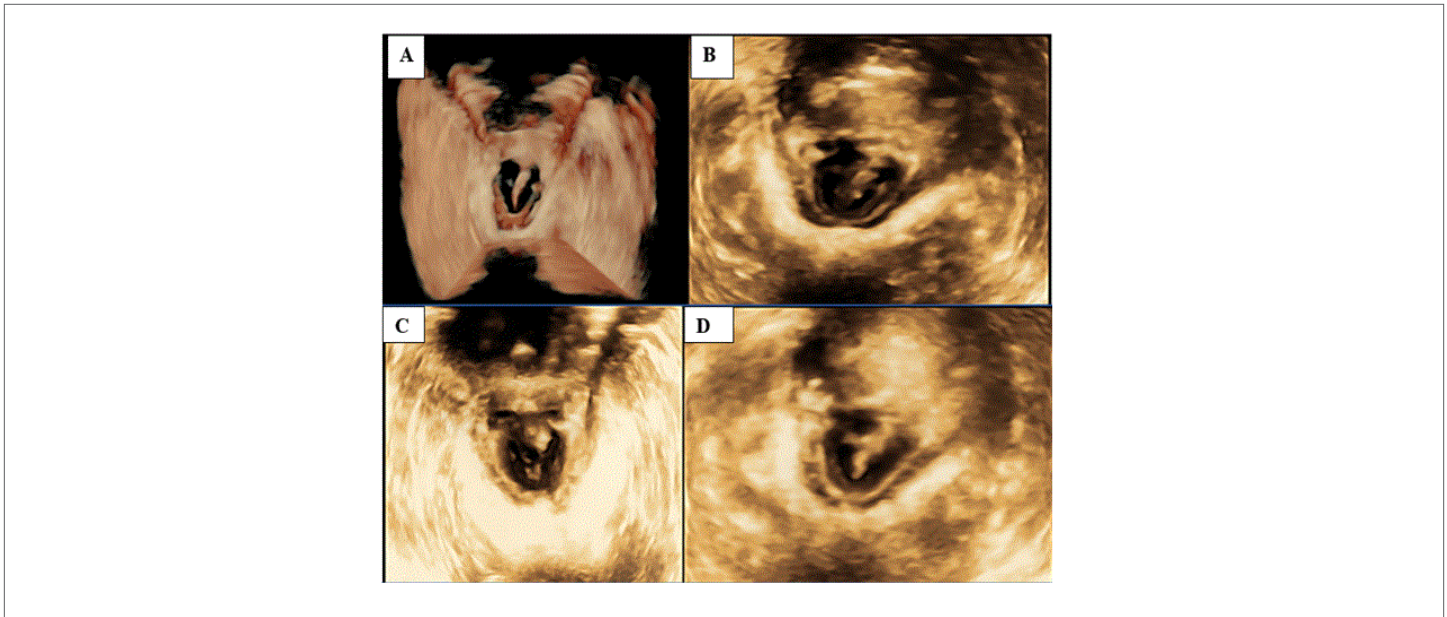
**Figure 8:** An image with 3DUS of a patient with complete perineal tear. There are two horse-shoe appearances, one of the EAS and the inner one of the IAS.



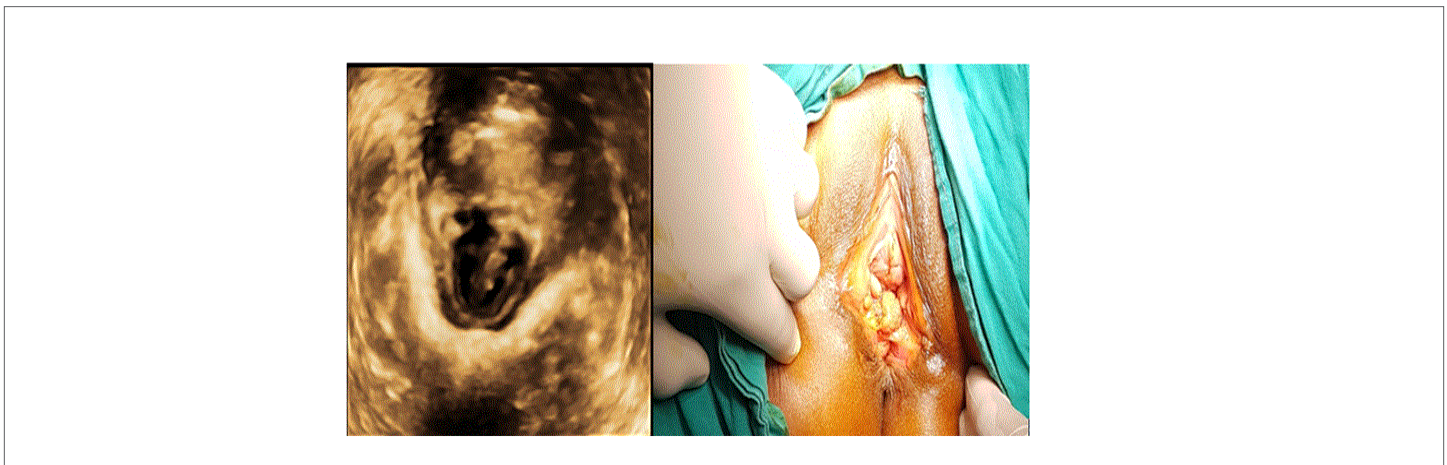
**Figure 9:** Images with 3DUS of patients with complete perineal tears, show torn posterior vaginal wall, anterior wall of the anal canal, the IAS and the EAS.



**Figure 10:** Steps of the posterior repair. Image 1 shows bulging posterior vaginal wall at rest, which means posteriorvaginal wall prolapse. Images 3, 4 & 5 show freeing the IAS from the posterior vaginal wall and then mending it. Images 6 & 7 show the two levator ani muscles are approximated but are kept untied till posterior vaginaloverlapisdone



**Figure 11:** Images with 3DUS of complete perineal tear, fourth degree, and the red arrows show horse-shoe appearance of torn EAS; while the blue arrows show torn IAS with a horse-shoe appearance.



**Figure 12:** Clinical and 3DUS pictures of complete perineal tear, there two horse-shoe appearance of the EAS and inside the IAS and torn posterior vaginal wall and anterior wall of the anal canal

Patients were assessed properly and had medical imaging with MRI or three dimension ultrasound (3DUS) imaging the rectum and the anal canal. All patients have FI and torn IAS as proved by medical imaging. Reconstructive surgery [12, 13, 14]: figure 10: In cases of FI and posterior vaginal wall prolapse, we correct the FI and the lacerated prolapsed posterior vaginal wall. We use hydro-dissection injecting 1/200,000 adrenaline on normal saline sub-vaginally and in the perineum. We expose the torn collagen chassis of the IAS by separating the torn collagen chassis of the IAS clear from the posterior vaginal wall, the lacerations in the anterior wall of the IAS will appear. Start mending the torn collagen chassis of the IAS using slowly absorbed suture material (vicryl number one zero)

by simple interrupted stitches; this may take 4-6 simple stitches. Approximate the two-levator ani muscles, using number one slowly absorbed suture material, leave the thread on pairs of artery forceps untied until later after overlapping the two longitudinal flaps of the posterior vaginal wall; two stitches to approximate the elevators may be enough. Strengthen the posterior vaginal wall by overlapping the two longitudinal vaginal flaps; also, we add extra support to the mended IAS, correct the posterior vaginal wall prolapse and narrow the patulous vagina. We approximate the two levator ani muscles by tying the threads by surgical knots. Finish by repairing the perineum. Fecal incontinence (FI) following complete perineal tear is corrected by this new reconstructive operation Reconstruction is done by five main steps:

1-Repair of the IAS,

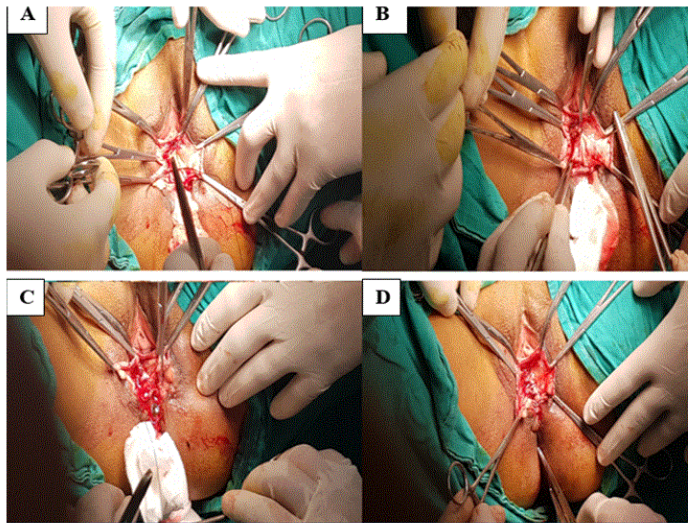
2-Repair of rectal and anal mucosa,

3-Repair of EAS,

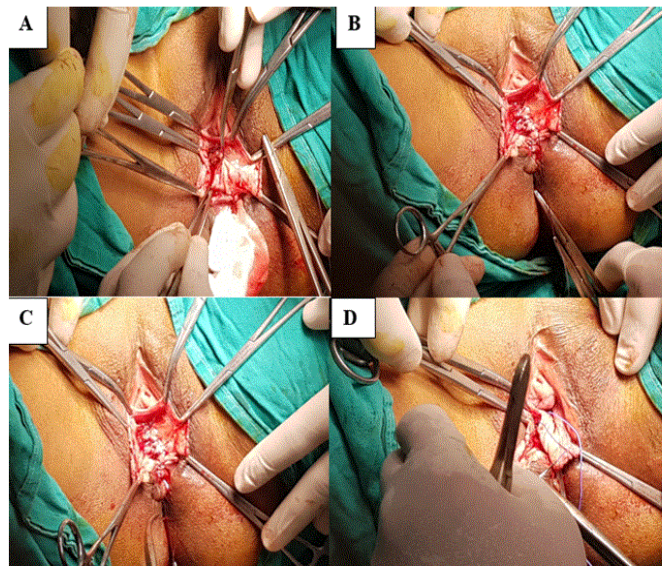
4-Repair of vaginal mucosa by overlapping the two vaginal flaps,

5-Repair of the perineum.

## Results



**Figure 13:** S: Steps of repair of complete perineal tear, image A is showing dissection of the IAS from the posterior vaginal wall. Image B is showing mending of the IAS. Image C is showing repair of the cut anal wall and the repair of the EAS end-to-end suture. Figure D is showing the internal anal sphincter repaired, the anal canal and the EAS repaired as well



**Figure 14:** Surgical repair of complete perineal tear, image A is mending the IAS. Image B is mending the torn edges of the EAS over the mended anal wall. Image C is approximating the two levator ani muscles. Image D is overlapping the two vaginal flaps over the mended IAS, the EAS and the approximated levator ani muscles, so we add extra support to the corrected anal sphincters and narrow the vaginal introitus.



---

---

## Results

Continence for flatus and feces is gained in all patients immediately and lasted for 12 months. After 12 month one patient failed in controlling flatus, and after 15 months another patient had failure in controlling flatus only. After 18 months a third patient had incontinence for flatus but not feces. The sum of failure for continence is partial failure and was in three patients after 18 months and this is statistically insignificant. Continence is gained immediately and on long term (up to 40 months follow up) except for three patients who had partial failure.

## Discussion

Anybody action is a nerve-muscle action controlled by an alert healthy nervous system. Fecal continence depends on a closed and empty anal canal created by two factors: one is an inherent factor and the other is acquired. The inherent factor is the presence of a healthy intact IAS which is a collagen-muscle tissue cylinder that surrounds the anal canal and is surrounded in its lower part with the EAS. The IAS is the pillar structure of fecal continence. The acquired factor is gaining (by toilet training) high sympathetic tone at the IAS keeping it contracted all the time until there is a desire and/or a need to evacuate at suitable social circumstances. This is a nerve-muscle action, nor-epinephrine (a neuro-transmitter of alpha-sympathetic nerves) acts on receptors on the plain muscle fibers of the IAS keeping it contracted all the time, and thus the anal canal empty and closed. FI can be due to neurological or muscular failure. The neurological failure can be transient (sympathetic failure) e.g. severe fear or getting drunk; or permanent (damage of CNS) e.g. stroke, MS and DLE. More commonly, the cause of FI is lacerations in the collagen chassis of the IAS which is the result of CBT. The IAS is intimately related to the posterior vaginal wall which is subjected to significant (sometimes rapid) stretching during vaginal delivery, with subsequent invisible lacerations in the collagen chassis of both the posterior vaginal wall and the IAS. The lacerated collagen chassis of both the posterior vaginal wall and the IAS become weaker with decrease of estrogen level, as the vitality of the pelvic tissues are hormone dependent. CBT may also cause various degrees of perineal lacerations which need reconstructive surgery. The perineum is the outermost layer of the pelvic floor closing the pelvic outlet. Although the EAS contributes to the mechanism of defecation control, yet the IAS is the pillar of fecal continence. So repair of only torn EAS fails to regain fecal continence. The crucial step towards gaining fecal continence is to mend the lacerated collagen chassis of the IAS. The EAS with its three parts (the deep, superficial and the subcutaneous) is a striated skeletal muscle, which has its nerve supply through the pudendal nerve, is a voluntary muscle. It relaxes voluntarily with matters (stools and/or flatus) in the anal canal; also it contracts rhythmically at the end of defecation to ensure complete expulsion of the anal contents and leave an empty and closed anal canal [15, 16, 17,18].

## The Internal anal Sphincter (IAS)

The IAS is a collagen-muscle tissue cylinder that surrounds the anal canal and is surrounded in its lower part with the external anal sphincter (EAS). The collagen is the strongest soft tissue in the body, and the muscle is plain smooth muscle fibers that lie on top and intermingle with the collagen fibers in its mid-section. The muscle has its nerve supply from the thoraco-lumbar sympathetic nerve plexus through the superior then the inferior hypogastric nerves. The IAS is the corner-stone in the structure of keeping fecal continence. Toilet training leads to high sympathetic nerve tension at the IAS, causing its sustained contraction all the time closing the anal canal until there is a need &/or a desire to pass flatus &/or feces at suitable social circumstances. Since the IAS is a collagen cylinder with plain muscle fibers lying on top of the midsection of the collagen cylinder, trauma causing lacerations of its collagen chassis can be from the outer surface of the cylinder (CBT) or from the inner surface of the collagen cylinder as for example anal intercourse. Whether the trauma affects the outer diameter of the cylinder (CBT), or the inner surface of the collagen chassis (anal intercourse) the result is torn weak IAS with subsequent FI. The partial failure gained by the three patients was in three patients who had long standing complete perineal lacerations which may cause fibrosis and degeneration in the collagen and caused its failure to regain its strength. The internal urethral sphincter (IUS) and the IAS share the same embryological origin and have the same neuro-vascular supply. Toilet training induces and maintains high sympathetic tone at both sphincters keeping them contracted all the time until there is a desire &/or a need to evacuate under suitable social circumstances. A distended rectum (by feces &/flatus) may give false sensations of a quick desire to urinate (OAB).

## References

1. El Hemaly AM, Mousa LA, Ibrahim M, Kandil IM, Morad MR, et al.( 2018) Urinary and Fecal Control and Incontinence: Pathogenesis and Man-agement . Med Sur Urol. an open access journal 7(3): DoI :10002003.
2. El Hemaly AM, Mousa LA, Ibrahim M, Korjak A, et al. (2018) Outlet Control, Pathogenesis and Treatment: The Role of Ultrasound in its Management. DSJUOG 12(1).
3. El Hemaly AM, Mousa LA, Ibrahim M, Kandil IM, Morad MR, et al. (2018) Overactive Bladder (OAB) New Concepts on its Pathophysiology. International Scientific Research Organization Journal (ISROJ) (3)2.
4. El Hemaly AM, Mousa LA, Ibrahim M, Kandil IM, Morad MR, et al ( 2018) Body Excreta Control and Incontinence. Med Sur Urol 7(1).

5. El Hemaly AM, Mousa LA, Ibrahim M, Kandil IM, Morad MR, et al (2016) Pelvic Floor Dysfunction: New Concepts on its Pathophysiology and its Reconstructive Surgery. *Gynecology & Obstetrics Case report*.
6. El Hemaly AM, Mousa LA, Ibrahim M, Kandil IM, Khaled A . (2014) Shehata, Imaging of the Pelvic Floor, *Current Medical Imaging Reviews* 10(3).
7. El Hemaly AM, Mousa LA, Ibrahim M, Kandil IM. (2014) Micturition and Urinary Incontinence. *Journal of Nephrology and Urology Research* (2).
8. El Hemaly AM, Mousa LA, Ibrahim M, Kandil IM, Kareem A, Adwani AI (2014) Pelvic Floor Dysfunction and its Reconstructive Surgery: Novel Concepts; Createspace.
9. El Hemaly AM, Mousa LA, Ibrahim M, Kandil IM, Sayed MS, et al. (2014) A Novel Concept on the Patho-Physiology of Defecation and Fecal Incontinence (FI) in Women-Moreover, Its Reconstructive Surgery; in: Anthony G. Catto-Smith, ed. *FECAL INCOTINENCE Causes, Management and Outcome*. INTECH Publication
10. El Hemaly AM, Mousa LA, Ibrahim M, Kurjak A, Kandil IM (2013) Pelvic Floor Dysfunction, the Role of Imaging and Reconstructive Surgery, *Donald School Journal of Ultrasound in Obstetrics and Gynecology, DSJUOG* 7(1).
11. El Hemaly AM, Mousa LA, Ibrahim M, Kurjak A, Kandil IM, et al. (2011) Ultrasound Assessment of the Internal Anal Sphincter in Women with Fecal Incontinence and Posterior Vaginal Wall Prolapse (Rectocele). *DSJUOG* 5( 4).
12. El Hemaly AM, Mousa LA, Ibrahim M, Kurjak A, Kandil IM, et al. (2009) Imaging the Internal Urethral Sphincter and the Vagina in Normal Women and Women Suffering from Stress Urinary Incontinence and Vaginal Prolapse. *Gynaecologia Et Perinatologia* 18(4).
13. El Hemaly AM, Mousa LA, Ibrahim M, Kurjak A, Kandil IM, et al. (2010) Fecal Incontinence, A Novel Concept: The Role of the internal Anal sphincter (IAS) in defecation and fecal incontinence. *Gynaecologia Et Perinatologia* 19( 2).
14. El Hemaly AM, Mousa LA, Ibrahim M, Kurjak A, Kandil IM, et al. (2010) Surgical Treatment of Stress Urinary Incontinence, Fecal Incontinence and Vaginal Prolapse By A Novel Operation "Urethro-Ano-Vaginoplasty" *Gynaecologia Et Perinatologia* 19( 3).
15. Rosenberg, Karen, Trevathan, Wenda (2002). "Birth, obstetrics and human evolution". *BJOG: An International Journal of Obstetrics and Gynaecology* 109 (11): 1199–1206. doi:10.1046/j.1471-0528.2002.00010.x
16. Eskandar O, Shet D (2009). Risk factors for 3rd and 4th degree perineal tear. *Journal of obstetrics and gynaecology* 29 (2): doi:10.1080/01443610802665090
17. Fernando RJ, Sultan AH, Kettle C, Radley S, Jones p, et al. (2006) Repair Techniques for Obstetric Anal Sphincter Injuries; Randomized Controlled Trial. *Obstetrics & Gynecology* 107(6).
18. Halverson AL, Hull TL (2000) Long-term outcome of overlapping anal sphincter repair; *Dis Colon Rectum* (45)3.