

## Case report

### Meckel's Diverticulum Masquerading as Rhabdomyosarcoma; A Rare Presentation

Sandesh V Parelkar<sup>1\*</sup>, Beejal V Sanghvi<sup>1</sup>, Satej S Mhaskar<sup>1</sup>, Shalil H Patil<sup>1</sup>, Natasha L Vageriya<sup>1</sup> and Devdas S Samala<sup>1</sup>

Department of Paediatric Surgery, Seth GSMC & KEM Hospital, Acharya Donde Rd, Parel, Mumbai, Maharashtra, India

#### Abstract

Meckel's diverticulum (M.D.) is the most common congenital anomaly of the gastrointestinal tract and is found in 1.2% to 3% of the population. Although the common presentations are diverticulitis and bleeding, it can occasionally have a confusing presentation. We report a one year old boy presenting with urinary symptoms with a mass felt anteriorly on per rectal examination. Radiological investigations suspected a rhabdomyosarcoma arising from posterior bladder wall inaccessible to biopsy. Cystoscopy did not reveal any growth; bladder mucosa was normal. On diagnostic laparoscopy, there was collection in the pelvis with M.D. which was inflamed and adherent to the posterior wall of urinary bladder. M.D. was delivered through the incision extended from umbilical port and resection anastomosis was done. Diagnostic laparoscopy helped us resolve the dilemma.

**Keywords:** Meckel's diverticulum; Rhabdomyosarcoma bladder; Diagnostic laparoscopy

#### Introduction

Meckel's Diverticulum (M.D.) is the commonest congenital anomaly of the gastrointestinal tract and is found in 1.2% to 3% of the population. [1-6] M.D. is a true diverticulum found on the antimesenteric border. Majority of symptomatic children are younger than 10 years [7] Hemorrhage and obstruction predominate in children while obstruction and inflammatory symptoms are commoner in adults [8,9,10,11,12,13] It can occasionally be associated with other anomalies like esophageal atresia, anorectal malformation and others as enlisted in table 1. It has wide variety of presentations and may mimic varied disease conditions.

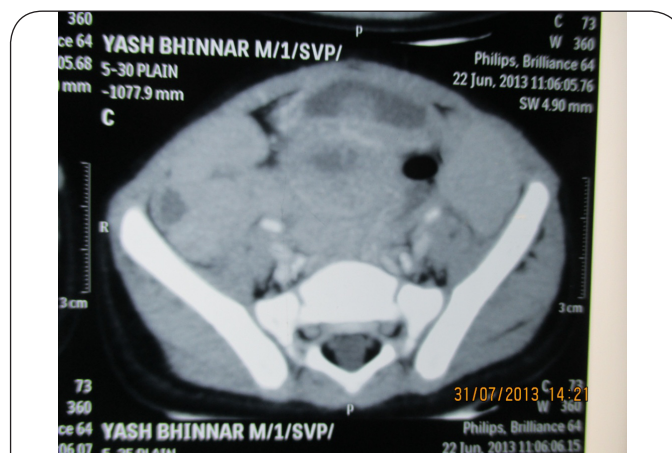
#### Associations (12) Table 1

• Esophageal atresia	• 12 %
• Anorectal malformation	• 11 %
• Neurologic abnormalities	• 6 %
• Congenital cardiovascular anomalies	• 4.6 %
• Duodenal atresia	• 4.2 %
• Crohn's disease	• 5.8 %

#### Case report

One year old boy presented with dysuria and pyuria for 6 days. Per abdomen was unremarkable, but on per rectal examination an ill defined, firm mass measuring approximately 3 x 3 cm. was palpable anteriorly. Overlying rectal mucosa was free. Ultrasound of the pelvis showed a hypoechoic, centrally necrotic mass posterior to the bladder measuring 3.5 x 3.1 cm and involving the posterior bladder wall, which was reported as rhabdomyosarcoma of urinary

bladder. Computed tomography (CT) scan of the abdomen and pelvis revealed a heterogenous mass of 5.5 cm diameter with central necrosis and extension into the posterior wall of urinary bladder without any conclusive inference. (Fig 1) On cystoscopy urethra was normal. Right Ureteric orifice seen over a bulge. Left Ureteric orifice was not visualized. Rest of the bladder was normal. Ultrasound guided biopsy was not possible as mass was surrounded by bowel loops, but the repeat ultrasound was reported to have a uterus-like structure posterior to urinary bladder. Thus diagnostic laparoscopy was proceeded with. Tip of M.D. was found adherent to posterior wall of bladder leading to pelvic abscess approximately 5 ml which was sealed off by the adhesions between sigmoid and bladder. M.D. was delivered through extended umbilical port incision and a resection anastomosis was done. (Fig 2, Fig 3) Post operative period was uneventful.



**Fig 1 :** Computed Tomography scan of abdomen and pelvis: heterogenous mass of 5.5 cm diameter with central necrosis and extension into the posterior wall of urinary bladder

**\*Corresponding author:** Sandesh V Parelkar Professor and Head Paediatric Surgery, Seth GSMC & KEM Hospital, Acharya Donde Rd, Parel, Mumbai, Maharashtra, India, Tel: +91 - 98690 39091; E-mail: sandeshparelkar@kem.edu

**Rec Date:** February 1 2016, **Acc Date:** February 8, 2016, **Pub Date:** February 8, 2016.

**Citation:** Sandesh V Parelkar, Beejal V Sanghvi, Satej S Mhaskar, Shalil H Patil, Natasha L Vageriya and Devdas S Samala (2016) Meckel's Diverticulum Masquerading as Rhabdomyosarcoma; A Rare Presentation. BAOJ Cancer Res Ther 2: 020.

**Copyright:** © 2016 Sandesh V Parelkar, et al. This is an open-access article distributed under the terms of the Creative Commons Attribution License, which permits unrestricted use, distribution, and reproduction in any medium, provided the original author and source are credited.

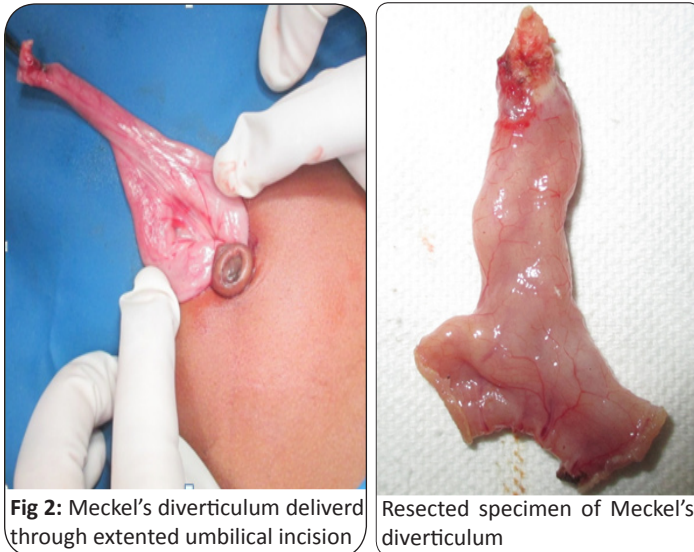


Fig 2: Meckel's diverticulum delivered through extended umbilical incision

Resected specimen of Meckel's diverticulum

## Discussion

Vitellointestinal duct (V.I.D) / omphalomesenteric duct (O.M.D) connects the yolk sac with the primitive midgut of fetus. The vitelline duct fuses with the body stalk to form the umbilical cord. Regression of VID normally occurs between 5th and 7th week of intrauterine life [1]. Failure of complete obliteration of VID can result in remnants and their symptoms. There are several anatomical variants of persistent vitellointestinal remnant. M.D. is by far the most common anomaly [13]. It was previously estimated that Meckel's Diverticulum can be found in 2% of the general population; however, more recent studies have shown this to be an overestimate, with the real incidence being approximately 1.2% based on a review of more than 50 years of autopsy studies [2,3,4]. It is situated in the antimesenteric border of small intestine, about 60 cms from ileocaecal valve and is usually 3-5 cm long. M. D occurs with equal frequency in both sexes, but symptomatic diverticula occur more commonly in males [8]. The commonest complications are lower gastrointestinal bleeding, intestinal obstruction, inflammatory complications and rarely neoplasia.

M.D. can notoriously masquerade as other disease conditions. Many atypical presentations of M.D. are reported. A retrospective study analysing hospital records of 30 years done by R. Rajendran et al S.A.T. Hospital, Kerala found the rare presentations of persistent VID. Most remarkable cases in their series were patent VID (Omphaloileal fistula) (5/132 cases) and umbilical cysts ( 3/132 cases) [14]. Congenital appendico-umbilical fistula is reported due to patent omphalomesenteric duct of the vermiform appendix [15]. Congenital fistulation of a M.D. to the surface of an exomphalos minor was reported by Hale [16]. Cystic M.D. as a cause of pelvic mass presenting with recurrent urinary infection [17] Vesico enteric fistula [18] and Subcutaneous abscess [19] are reported in elder population. Most of the case reports mentioning Meckel's diverticulum presenting with urological symptoms are from adult population [20]. In our case M.D. posed a diagnostic dilemma, masquerading as a grave diagnosis of rhabdomyosarcoma, to be confirmed only on diagnostic laparoscopy. It was inflamed and forming an abscess in to the posterior wall of bladder after adhering to it.

## Conclusion

Though M.D. commonly presents as bleeding and obstruction, it can rarely mislead us with its rarer presentations and warrants due consideration while diagnosing them. It is the most common congenital anomaly of gastrointestinal tract and as reported above can present with urinary symptoms and physical findings which are difficult to attribute to such a rare presentation.

## References

1. Albu I, Munteanu V, Florescu P, Petrescu M, Olteanu L, et al. (1993) The ileal diverticulum. Morpho-clinical and epidemiological study. Rom J Morphol Embryol 39: 37-42.
2. Cserni G (1996) Gastric pathology in Meckel's diverticulum. Review of cases resected between 1965 and 1995. Am J Clin Pathol 106: 782-785.
3. Matsagas MI, Fatouros M, Koulouras B, Giannoukas AD (1995) Incidence, complications, and management of Meckel's diverticulum. Arch Surg 130: 143-146.
4. Zani A, Eaton S, Rees CM, Pierro A (2008) Incidentally detected Meckel diverticulum: to resect or not to resect? Ann Surg 247: 276-281.
5. Zani A, Eaton S, Rees CM, Pierro A (2008) Incidentally detected Meckel diverticulum: To resect or not to resect?. Ann Surg 247: 276-281.
6. Ueberrueck T, Meyer L, Koch A, Hinkel M, Kube R, et al. (2005) The significance of Meckel's diverticulum in appendicitis - a retrospective analysis of 233 cases. World J Surg. 29: 455-458.
7. Skandalakis E, et al (1994) The small intestines. In Skandalakis]E, Gray SW (eds): Embryology for Surgeons, 2nd ed. Baltimore, Williams & Wilkins, p 184.
8. Mackey WC, Dineen P (1983) A fifty year experience with Meckel's diverticulum. Surg Gynecol Obstet. 156:56-64.
9. St-Vil D, Brandt ML, Panic S, Bensoussan AL, Blanchard H (1991) Meckel's diverticulum in children: A 20-year review. J Pediatr Surg. 26: 1289-1292.
10. Rutherford RB, Akers DR (1966) Meckel's diverticulum: A review of 148 pediatric patients, with special reference to the pattern of bleeding and to mesodiverticular vascular bands. Surgery 59: 618-626.
11. Bemelman WA, Hugenholtz E, Heij HA, Wiersma PH, Obertop H (1995) Meckel's diverticulum in Amsterdam: Experience in 136 patients. World J Surg 19: 734-736 discussion 737.
12. Menezes M, Tareen F, Saeed A, Khan N, Puri P (2008) Symptomatic Meckel's diverticulum in children: A 16-year review. Pediatr Surg Int 24: 575-577.
13. Simms MH, Corkery JJ (1980) Meckel's diverticulum: its association with congenital malformation and the significance of atypical morphology. Br J Surg 67(3): 216-219.
14. Rajendran R, Daniel VS, NoorSathar NS, Varghese SA (2008) Clinico-Pathology study of Vitellointestinal remnants in children. KMJ issue 2 August 2008.
15. Crankson SJ, Ahmed GS, Polkar V (1998) Patent omphalomesenteric duct of the vermiform appendix in a neonate : congenital appendicoumbilical fistula. Pediatr Surg Int 14(3): 229-230.
16. Hale PC, Agarwal M (1993) Congenital fistulation of a Meckel's diverticulum to the surface of an exomphalos sac. Br J Clin Pract; 47(5): 273.

17. Oguzkurt P, Arda IS, Kayaselcuk F, Barutcu O, Oguzkurt L (2001) Cystic Meckel's diverticulum: A rare cause of cystic pelvic mass presenting with urinary symptoms. *J Pediatr Surg* 36(12): 1855-1858.
18. Bouassida M, Mighri MM, Trigui K, Chtourou FM, Sassi S et al.(2013) Meckel's diverticulum: an exceptional cause of vesicoenteric fistula: case report and literature review. *Pan Afr Med J* 15:19.
19. Karatepe O, Adas G, Altok M, Ozcan D, Kamali S, et al. (2009) Meckel's diverticulum manifested by a subcutaneous abscess. *World J Gastroenterol* 15(48): 6123–6125.
20. Wong BS, Larson DW, Smyrk TC, Oxentenko AS (2010) Perforated Meckel's diverticulum presenting with combined bowel and urinary obstruction and mimicking Crohn's disease: a case report. *Journal of Medical Case Reports* 4:264.